

 Join Whatsapp

www.freejobalert.com
Free Job Alert
.com

 Download App

UPSC CMS Previous Year Question Papers 2019 Paper 1

FreeJobAlert.com



Join Whatsapp

www.freejobalert.com
Free Job Alert
.com



Download App

1.

Austin Flint Murmur occurs in:

- (a) Severe Mitral Stenosis
- (b) Severe Mitral Regurgitation
- (c) Severe Aortic Regurgitation
- (d) Severe Aortic Stenosis

2.

Which amongst the following should be considered in a patient with acute chest pain and ST segment elevation in the precordial leads?

- 1. Acute myocardial infarction
- 2. Acute hyperkalemia
- 3. Pericarditis
- 4. Hypocalcemia
- 5. Oesophagitis
- 6. Pneumothorax

Select the correct answer using the code given below.

- (a) 1, 2 and 3
- (b) 1, 3 and 4
- (c) 1, 4 and 5
- (d) 2, 3 and 6

3.

Which amongst the following is the most powerful independent risk factor for atherosclerosis?

- (a) Age
- (b) Hypertension

(c) Gender

(d) Physical Activity

4.

In which of the following SA node dysfunction conditions, permanent pacing may NOT be required?

1. Beta blocker drugs
2. Narcotic drugs
3. Iatrogenic–Post RT/Surgery
4. Hypothyroidism
5. Sick sinus syndrome
6. Raised Intracranial tension

Select the correct answer using the code given below.

- (a) 1, 2, 3 and 4
- (b) 1, 2, 4 and 5
- (c) 1, 2, 4 and 6
- (d) 3, 5 and 6

5.

Kartagener syndrome has the following features EXCEPT:

- (a) Recurrent Sinusitis
- (b) Transposition of Viscera
- (c) Autosomal Dominant
- (d) Bronchiectasis



Join Whatsapp

www.freejobalert.com
Free Job Alert
.com



Download App

6.

Which of the following pulmonary function set is characteristic of COPD?

- (a) FEV1 / FVC < 70% ; FEV1 ↓ ; FVC ↓ ; TLC ↑ DLCO Normal
- (b) FEV1 / FVC < 70% ; FEV1 ↑ ; FVC ↓ ; TLC ↓ DLCO ↓
- (c) FEV1 / FVC < 70% ; FEV1 ↓ ; FVC ↑ ; TLC ↑ DLCO ↑
- (d) FEV1 / FVC < 70% ; FEV1 ↓ ; FVC ↓ ; TLC ↓ DLCO ↓

7.

Which of the following drugs causes dry cough as a side effect?

- (a) Fluconazole
- (b) Ramipril
- (c) Cefixime
- (d) Atenolol

8.

For Acid Fast Bacilli (AFB) to be detected in sputum by the direct microscopy, the bacillary burden in sputum typically is:

- (a) 500–1,000 organisms
- (b) 5,000–10,000 organisms
- (c) 10,000–20,000 organisms
- (d) Any number of organisms

9.

The pleural fluid is considered as empyema if following is present in it:

- (a) Fluid glucose < 60 mg/dl
- (b) Lactate Dehydrogenase (LDH) of more than 1000 U/L
- (c) Fluid pH of less than 7.0



Join Whatsapp

www.freejobalert.com
Free Job Alert
.com



Download App

(d) All of these

10.

Airway secretions contain all of the following antimicrobial peptides EXCEPT:

(a) Defensins

(b) Immunoglobulin A (IgA)

(c) Lysozyme

(d) Histidine

11.

The respiratory motor neuron associated with origin of respiratory cycle is located in:

(a) Pons

(b) Posterior Medulla oblongata

(c) Ventral Medulla oblongata

(d) Mid brain

12.

Consider the following statements regarding Weight Loss:

1. 4.5 kg over 6-12 months

2. 10 kg over 6-12 months

3. More than 5 % over 6-12 months

4. More than 10 % over 6-12 months

Which of the above constitute significant or clinically important weight loss?

(a) 1 and 3

(b) 1 and 4

(c) 2 and 3



Join Whatsapp

www.freejobalert.com
Free Job Alert
.com



Download App

(d) 2 and 4

13.

Which of the following Ascitic Fluid analysis is most compatible with a diagnosis of Ascites secondary to portal hypertension?

- (a) SAAG < 1.1 g/dl ; Ascitic Fluid Protein < 2.5 g/dl
- (b) SAAG < 1.1 g/dl ; Ascitic Fluid Protein > 2.5 g /dl
- (c) SAAG > 1.1 g/dl ; Ascitic Fluid Protein < 2.5 g /dl
- (d) SAAG > 1.1 g/dl ; Ascitic Fluid Protein > 2.5 g /dl

14.

All are the causes of Interstitial lung disease EXCEPT:

- (a) Idiopathic Pulmonary Fibrosis
- (b) Granulomatosis with Polyangiitis
- (c) Sarcoidosis
- (d) Bronchial Asthma

15.

The rhythmic activity recorded on scalp by EEG in a normal awake adult lying quietly with eyes closed is:

- (a) Less than 4Hz – Delta rhythm
- (b) 4 to 7 Hz –Theta rhythm
- (c) 8 to 13 Hz – Alpha rhythm
- (d) More than 14 Hz –Beta rhythm

16.

Transient Monocular blindness may be due to small platelet emboli that occludes:

- (a) Posterior Cerebellar artery



Join Whatsapp

www.freejobalert.com
Free Job Alert
.com



Download App

(b) Posterior Cerebral artery

(c) Ophthalmic artery

(d) Vertebral artery

17.

The phenomenon of sparing of macular vision is due to collateral circulation between:

(a) middle and posterior cerebral artery

(b) anterior and middle cerebral artery

(c) anterior and posterior cerebral artery

(d) anterior, middle and posterior cerebral artery

18.

Characteristic features of Horner's Syndrome are:

(a) partial ptosis, enophthalmos, constricted pupil, decreased sweating

(b) partial ptosis, exophthalmos, constricted pupil, decreased sweating

(c) partial ptosis, enophthalmos, dilated pupil, decreased sweating

(d) partial ptosis, enophthalmos, constricted pupil, increased sweating

19.

All of the following statements are true EXCEPT:

(a) Dorsal column fibres synapse at the cuneate and gracile nuclei

(b) Pain and temperature sensations are carried by lateral spinothalamic tract

(c) Spinal cord ends at lower level of 5th lumbar vertebrae

(d) Dorsal spinocerebellar tract carries fibres from the same side of the body

20.

The following conditions usually present with proximal muscle weakness, EXCEPT:



Join Whatsapp

www.freejobalert.com
Free Job Alert
.com



Download App

- (a) Facio-scapulo-humeral dystrophy
- (b) Myotonia dystrophica
- (c) Duchene's muscular dystrophy
- (d) Becker muscular dystrophy

21.

Pel-Ebstein fever is seen in:

- (a) Hodgkin's disease
- (b) Malaria
- (c) Kalazar
- (d) Typhoid fever

22.

All of the following are true regarding acute leukaemias, EXCEPT:

- (a) Promyelocytic leukaemia may present with DIC
- (b) Gum hypertrophy is a feature of monocytic leukaemia
- (c) Translocation is a common chromosomal abnormality in acute myeloid leukaemia
- (d) Auer rods suggest acute lymphocytic leukaemia

23.

All of the following are clinical features of Polycystic ovarian syndrome EXCEPT:

- (a) Menorrhagia
- (b) Hirsutism
- (c) Glucose intolerance
- (d) Infertility

24.

Clinical features of Turner syndrome include all EXCEPT:

- (a) Webbing of Neck
- (b) Narrow carrying angle of Elbow
- (c) Coarctation of Aorta
- (d) Short stature

25.

Pretibial myxedema is a clinical feature of:

- (a) Hypothyroidism
- (b) Graves disease
- (c) Cushing disease
- (d) Conn syndrome

26.

Match the List I with List II and select the correct answer using the code given below the lists:

List I	List II
(disease)	(signs)
A. Conn syndrome	1. Anosmia
B. Turner syndrome	2. Tetany
C. Kallman syndrome	3. Lymphoedema
D. Cushing syndrome	4. Avascular necrosis of hip

Code:

- (a) A-4 B-1 C-3 D-2
- (b) A-2 B-3 C-1 D-4



Join Whatsapp

www.freejobalert.com
Free Job Alert
.com



Download App

(c) A-2 B-1 C-3 D-4

(d) A-4 B-3 C-1 D-2

27.

Which of the following is NOT a part of Koch's postulates?

(a) The same organism must be present in every case of the disease

(b) The organism must be isolated from the diseased host and grown in culture

(c) The isolate must cause the disease when incubated

(d) The organism may not be reisolated from the incubated diseased host

28.

All of the following cause dementia EXCEPT:

(a) Huntington's disease

(b) Alzheimer's disease

(c) Vitamin D toxicity

(d) Thiamine deficiency

29.

The therapeutic level of Digoxin in blood is:

(a) 1–2 ng/ml

(b) 4–6 ng/ml

(c) 6–8 ng/ml

(d) 8–10 ng/ml

30.

A 40-year old woman presents with sudden onset palpitations. An ECG done reveals narrow QRS complex tachycardia. The most likely diagnosis is:

(a) Ventricular tachycardia



Join Whatsapp

www.freejobalert.com
Free Job Alert
.com



Download App

- (b) Pre-excited tachycardia
- (c) Paroxysmal supraventricular tachycardia with aberrancy
- (d) AV reentry tachycardia

31.

Which of the following statements are true about management of acute pulmonary oedema?

1. Put the patient in relaxed, supine position
2. Give high flow, high concentration oxygen
3. Administer Furosemide intravenously
4. No role of Nitrates

Select the correct answer using the code given below:

- (a) 1 and 2
- (b) 2 and 3
- (c) 3 and 4
- (d) 1 and 4

32.

Which of the following does NOT cause prolongation of QT interval?

- (a) Hypomagnesaemia
- (b) Hyperkalaemia
- (c) Erythromycin
- (d) Amiodarone

33.

A 21-year young man presents in emergency with high grade fever with inflammation of knee and ankle joints which is fleeting in nature. There is history of occasional palpitations. There is no history of antecedent sore throat.



Join Whatsapp

www.freejobalert.com
Free Job Alert
.com



Download App

On examination, splenomegaly is present. The ECG shows prolongation of PR interval. What is the most likely diagnosis in India?

- (a) Still disease
- (b) Enteric fever
- (c) Rheumatic fever
- (d) Reiter's syndrome

34.

A 50-year gentleman with Type-2 Diabetes mellitus for 5 years presents in medical emergency with sudden onset of dyspnoea at rest, orthopnoea, and prostration. On examination, pulse is rapid and very weak in volume. His blood pressure is 100/70 mmHg. There are diffuse crepitations at lung bases. What is the most likely diagnosis of his conditions?

- (a) Mitral stenosis with bacterial endocarditis
- (b) Right heart failure
- (c) Left heart failure
- (d) Constrictive pericarditis

35.

The 'Y' descent in JVP waveform represents:

- (a) Atrial relaxation
- (b) Atrial systole
- (c) Atrial emptying
- (d) Apical displacement of tricuspid valve

36.

While distinguishing a venous pulsation from the arterial pulsation in neck, which of the following is NOT correct?

- (a) The height of venous pulse varies with respiration
- (b) Abdominal pressure causes rise in venous pulse



Join Whatsapp

www.freejobalert.com
Free Job Alert
.com



Download App

(c) Venous pulse has a single peak in each cardiac cycle

(d) Venous pulse is not easily palpable

37.

Which of the following does NOT cause pulmonary infiltrates with eosinophilia?

(a) Bronchial asthma

(b) Postradiation pneumonitis

(c) Eosinophilic granulomatosis with polyangiitis

(d) Cystic fibrosis

38.

Total lung capacity is decreased in which one of the following conditions?

(a) Asthma

(b) Chronic bronchitis

(c) Pulmonary fibrosis

(d) Emphysema

39.

Which one of the following is the minimum spirometry criterion for diagnosis of bronchial asthma?

(a) Decrease in FEV1 \geq 20 % after 6 minutes of exercise

(b) Increase in FEV1 \geq 12 % following administration of inhaled bronchodilators

(c) Increase in 500 ml of FEV1 after glucocorticoids inhalation

(d) Less than 20 % diurnal variation on more than 3 days a week on PEF diary

40.

Modified Blatchford score is used for the risk stratification of:

(a) Pancreatitis

- (b) Sepsis
- (c) Upper gastrointestinal bleeding
- (d) Cholangitis

41.

Long term use of proton pump inhibitor in elderly puts the patient at risk of which of the following?

1. Community acquired pneumonia
2. Clostridium difficile associated disease
3. Urinary tract infection

Select the correct answer using the code given below:

- (a) 1 only
- (b) 2 only
- (c) 1 and 2
- (d) 2 and 3

42.

Regardless of the infectious agent, the most characteristic symptom of infectious esophagitis is:

- (a) Dysphagia
- (b) Chest pain
- (c) Odynophagia
- (d) Haematemesis

43.

The parameters used in modified Child-Pugh classification for staging cirrhosis are:

- (a) Serum bilirubin, serum albumin only



Join Whatsapp

www.freejobalert.com
Free Job Alert
.com



Download App

- (b) Serum albumin, serum bilirubin, prothrombin time only
- (c) Serum albumin, serum bilirubin, prothrombin time, ascities only
- (d) Serum albumin, Serum bilirubin, prothrombin time, ascities, hepatic encephalopathy

44.

All of the following are consistent with a diagnosis of Irritable Bowel Syndrome EXCEPT:

- (a) Recurrent lower abdominal pain
- (b) Altered bowel habits
- (c) Symptoms during periods of stress
- (d) Weight loss

45.

A 26-year old HIV infected male presents with odynophagia. Upper GI endoscopy demonstrates serpiginous ulcers in a normal surrounding mucosa in distal esophagus. The most likely diagnosis is:

- (a) Gastro esophageal reflux disease
- (b) Cytomegalovirus esophagitis
- (c) Candida esophagitis
- (d) Herpetic esophagitis

46.

Cytomegalovirus esophagitis is particularly common in which group of patients?

- (a) Diabetes mellitus
- (b) Chronic liver disease
- (c) Alcoholics
- (d) Organ transplant recipients



Join Whatsapp

www.freejobalert.com
Free Job Alert
.com



Download App

47.

Which of the following is the most important complication in a patient with coeliac disease, who was previously doing well on a gluten-free diet and is now not responding to gluten restriction?

- (a) Intestinal infection
- (b) Intestinal lymphoma
- (c) Resistant coeliac disease
- (d) Type II Diabetes mellitus

48.

Which of the following are potential side effects of Anti-TNF therapies?

- 1. Infusion reactions
- 2. Melanoma
- 3. T-cell lymphoma

Select the correct answer using the code given below:

- (a) 1 and 3 only
- (b) 2 and 3 only
- (c) 1 and 2 only
- (d) 1, 2 and 3

49.

Presence of gastrinoma tumor should be suspected in which of the following conditions?

- 1. Ulcers in unusual location
- 2. Ulcers in the presence of H. pylori
- 3. Ulcers with frank complication like perforation

Select the correct answer using the code given below:



Join Whatsapp

www.freejobalert.com
Free Job Alert
.com



Download App

- (a) 1, 2 and 3
- (b) 2 and 3 only
- (c) 1 and 3 only
- (d) 1 and 2 only

50.

Coeliac disease is associated with which of the following medical conditions?

1. Dermatitis herpetiformis
2. Diabetes mellitus type II
3. Turner syndrome
4. IgA deficiency

Select the correct answer using the code given below:

- (a) 1, 2 and 3
- (b) 2, 3 and 4
- (c) 1, 3 and 4
- (d) 1, 2 and 4

51.

Which of the following features are characteristics of Whipple disease?

1. Migratory small joint arthropathy
2. Diarrhoea with steatorrhea
3. Weight loss with Arthralgia
4. Ophthalmic and CNS symptoms

Select the correct answer using the code given below:

- (a) 1, 2 and 3
- (b) 2, 3 and 4

(c) 1, 3 and 4

(d) 1, 2 and 4

52.

Which of the following are suggestive of protein losing enteropathy?

1. Steatorrhoea and diarrhoea
2. Peripheral oedema
3. Marked reduction of serum albumin with normal serum globulin

Select the correct answer using the code given below:

(a) 1 and 2 only

(b) 2 and 3 only

(c) 1 and 3 only

(d) 1, 2 and 3

53.

Which of the following statements regarding Ankylosing spondylitis (AS) are true?

1. AS occurs in about 10 % of Inflammatory Bowel Disease (IBD) patients
2. The AS activity is related to Bowel activity in IBD patients
3. The AS activity does remit with glucocorticoids or colectomy in IBD patients

Select the correct answer using the code given below:

(a) 2 and 3

(b) 1 and 3

(c) 3 only

(d) 1 only

54.



Join Whatsapp

www.freejobalert.com
Free Job Alert
.com



Download App

Which of the following are the renal complications of radiological investigations?

1. Contrast nephrotoxicity
2. Cholesterol atheroembolism
3. Nephrogenic sclerosing fibrosis of skin

Select the correct answer using the code given below:

- (a) 1 and 2 only
- (b) 2 and 3 only
- (c) 1 and 3 only
- (d) 1, 2 and 3

55.

A middle aged diabetic male who has recurrent chest pain undergoes coronary artery angiogram. The following day, he develops haematuria, proteinuria and renal impairment.

What is the most likely diagnosis?

- (a) Renal artery stenosis
- (b) Acute renal infraction
- (c) Atheroembolism
- (d) Haemolytic Uraemic syndrome

56.

Which of the following are contraindications for renal biopsy?

1. Normal size kidney
2. Uncontrolled hypertension
3. Solitary kidney
4. Disordered coagulation



Join Whatsapp

www.freejobalert.com
Free Job Alert
.com



Download App

Select the correct answer using the code given below:

- (a) 1, 2 and 4
- (b) 1, 2 and 3
- (c) 2, 3 and 4
- (d) 1, 3 and 4

57.

The most specific test that establishes the diagnosis of Myasthenia gravis is:

- (a) Anti-acetylcholine receptor antibody
- (b) Repetitive nerve stimulation test
- (c) Edrophonium test
- (d) MRI brain

58.

The commonest cause for new-onset seizures in patients older than 65 years is:

- (a) Trauma
- (b) Cerebrovascular disease
- (c) Tumors
- (d) Degenerative disease

59.

Ipsilateral 3rd cranial nerve palsy with contralateral cerebellar signs is seen in:

- (a) Weber syndrome
- (b) Wallenberg syndrome
- (c) Parinaud syndrome
- (d) Claude syndrome



Join Whatsapp

www.freejobalert.com
Free Job Alert
.com



Download App

60.

Incongruous contralateral homonymous hemianopia is due to lesion at:

- (a) Optic nerve
- (b) Optic chiasma
- (c) Optic tract
- (d) Optic radiation

61.

Macrocytosis is seen in all of the following conditions EXCEPT:

- (a) Liver disease
- (b) Post splenectomy
- (c) Hypothyroidism
- (d) Myelodysplastic syndrome

62.

All of the following cause microcytic hypochromic anemia EXCEPT:

- (a) Thalassemia
- (b) Anemia of chronic disease
- (c) Sideroblastic anemia
- (d) Haemolytic uraemic syndrome

63.

Treatment with the following drugs can lead to neutropenia EXCEPT:

- (a) Glucocorticoids
- (b) Propylthiouracil
- (c) Dapsone
- (d) Enalapril



Join Whatsapp

www.freejobalert.com
Free Job Alert
.com



Download App

64.

Which one of the following is a cause of early (0–4 weeks) infection in recipients of haematopoietic stem cell transplantation?

- (a) Cytomegalovirus
- (b) Pneumocystis jirovecii
- (c) Varicella zoster
- (d) Herpes simplex

65.

Which of the following is/are neurological manifestation(s) of vitamin B12 deficiency?

1. Poor memory
2. Optic atrophy
3. Personality change

Select the correct answer using the code given below:

- (a) 1 and 2 only
- (b) 3 only
- (c) 2 only
- (d) 1, 2 and 3

66.

Which of the following infections does NOT cause cold antibodies immune haemolysis?

- (a) Mycoplasma
- (b) Malaria
- (c) Syphilis
- (d) Epstein–Barr virus



Join Whatsapp

www.freejobalert.com
Free Job Alert
.com



Download App

67.

Which of the following test has maximum sensitivity for diagnosing Pheochromocytoma?

- (a) MIBG scintigraphy
- (b) Somatostatin receptor scintigraphy
- (c) Fluro-DOPA PET scan
- (d) 24 hours urinary fractionated metanephrines and catecholamines

68.

Which of the following does NOT causes polyuria?

- (a) Diabetes mellitus
- (b) Diabetes insipidus
- (c) Hypoparathyroidism
- (d) Conn syndrome

69.

A 24 year female presented with generalized weakness. Her thyroid function test is as follows. Serum T3 = Normal, T4 = Normal, TSH = 10mU/L. What is the most likely diagnosis?

- (a) Primary hypothyroidism
- (b) Secondary hypothyroidism
- (c) Subclinical hypothyroidism
- (d) Non thyroidal illness

70.

A 26 year old lady has a Prolactinoma (microadenoma). The best modality of treatment for her condition is:

- (a) Oral Cabergoline
- (b) Oral Bromocriptine



Join Whatsapp

www.freejobalert.com
Free Job Alert
.com



Download App

(c) Surgery

(d) Radiotherapy

71.

A 30-year woman in first trimester of pregnancy has Graves' disease. The treatment of choice is:

(a) Radioiodine

(b) Subtotal thyroidectomy

(c) Carbimazole

(d) Propylthiouracil

72.

The gold standard for diagnosis of Wilson's disease is:

(a) Demonstration of Kayser-Fleischer rings

(b) Urinary copper excretion

(c) Serum ceruloplasmin

(d) Liver biopsy with quantitative copper assays

73.

A 32-year old HIV infected male presents with shortness of breath and moderate fever of two- week duration. On examination, cyanosis is present, with respiratory rate of 22/minute and some basal crackles in chest. The CT chest shows bilateral ground-glass pattern. The most likely etiologic diagnosis is:

(a) Streptococcus pneumoniae

(b) Pneumocystis jirovecii

(c) Mycobacterium tuberculosis

(d) Staphylococcus sp.

74.

A 22-year old male is admitted with fever and altered consciousness for two days. Examination reveals nuchal rigidity and diffuse petechial rash on the trunk and lower extremities. The most likely etiologic agent is:

- (a) Escherichia coli
- (b) Streptococcus pneumoniae
- (c) Neisseria meningitidis
- (d) Haemophilus influenzae

75.

The drug of choice for the treatment of severe falciparum malaria in a 32-week pregnant woman is:

- (a) Artesunate
- (b) Quinine
- (c) Chloroquine
- (d) Quinidine

76.

A 36-year old chronic alcoholic, malnourished male is hospitalized with pneumonia. His condition worsens after aggressive treatment with intravenous dextrose and antibiotics. This phenomenon of 'Refeeding Syndrome' is accompanied by which one of the following biochemical alterations?

- (a) Hypophosphatemia
- (b) Hyponatremia
- (c) Hyperkalemia
- (d) Hypermagnesemia

77.

A 28-year old man weighs 80 kg and has a height of 150 cm. Based on his body mass index, he will be categorized as:

- (a) Normal

- (b) Underweight
- (c) Overweight
- (d) Obese

17

78.

Angular stomatitis and cheilosis are indicative of deficiencies of which of the following vitamins?

1. Riboflavin
2. Pyridoxine
3. Thiamine
4. Niacin

Select the correct answer using the code given below:

- (a) 1, 2 and 3
- (b) 1, 2 and 4
- (c) 2, 3 and 4
- (d) 1, 3 and 4

79.

Which of the following statements about "Early onset Osteoarthritis" are true?

1. Onset is usually before the age of 55 years
2. There is clear history of previous trauma
3. In most cases, single joint is affected

Select the correct answer using the code given below:

- (a) 1 and 2 only
- (b) 2 and 3 only



Join Whatsapp

www.freejobalert.com
Free Job Alert
.com



Download App

(c) 1 and 3 only

(d) 1, 2 and 3

80.

A 31-year young man presents with fever, weight loss, pain with swelling of knee joint and low backache with stiffness. Three weeks earlier, he was treated for symptoms of urinary tract infection by local practitioner. The joint aspirate is leucocyte rich and contains multinucleated macrophages. His urine culture is sterile. What is the most probable diagnosis?

(a) Septic arthritis

(b) Crystal arthritis

(c) Reactive arthritis

(d) Still disease

81.

Consider the following statements regarding Gout in old age.

1. Most of older patients have gout secondary to diuretic use and chronic kidney disease

2. Joints of the upper limbs are more frequently affected

3. Presentation is typical with acute attack of gout

Which of the statements given above are correct?

(a) 1 and 2 only

(b) 2 and 3 only

(c) 1 and 3 only

(d) 1, 2 and 3

82.

A 28-year old woman complains of arthritis involving bilateral metacarpophalangeal,



Join Whatsapp

www.freejobalert.com
Free Job Alert
.com



Download App

proximal interphalangeal and wrist joints of one year duration. The most likely disease entity

is:

- (a) Systemic lupus erythematosus
- (b) Ankylosing spondylitis
- (c) Rheumatoid arthritis
- (d) Osteoarthritis

83.

Which of the following are the complications of Rheumatoid arthritis?

1. Peripheral entrapment neuropathies
2. Subluxation of the cervical spine at the atlanto-axial joint
3. Primary amyloidosis
4. Lymphoma

Select the correct answer using the code given below:

- (a) 1, 2 and 3
- (b) 2, 3 and 4
- (c) 1, 3 and 4
- (d) 1, 2 and 4

84.

Which of the following is an Interleukin-17A (IL-17A) antibody?

- (a) Ustekinumab
- (b) Infliximab
- (c) Secukinumab
- (d) Etanercept



Join Whatsapp

www.freejobalert.com
Free Job Alert
.com



Download App

85.

The mainstay treatment of bipolar disorders is:

- (a) Oxcarbazine
- (b) Lithium
- (c) Risperidone
- (d) Olanzapine

86.

During assessment of hearing in a 30-year old male, the Weber test reveals perceived tone in the left ear. He is likely to be suffering from:

- (a) Left sensorineural deafness
- (b) Left conductive deafness
- (c) Right sensorineural deafness
- (d) Right conductive deafness

87.

A 56-year old man presented with acute onset aphasia. Speech output was markedly reduced with preserved comprehension of spoken language. The area of brain involved is:

- (a) Posterior part of temporal lobe
- (b) Cerebellum
- (c) Midbrain
- (d) Inferior frontal gyrus

88.

A 30-year old male was being evaluated for paraparesis. On examination, there was severe muscle atrophy, with absent deep tendon reflexes and absent Babinski sign. The most likely possibility is:

- (a) Upper motor neuron disease



Join Whatsapp

www.freejobalert.com
Free Job Alert
.com



Download App

- (b) Lower motor neuron disease
- (c) Psychogenic cause
- (d) Cerebellar disease

89.

A 16-year old boy presented with fever and a diffuse maculopapular rash. Examination revealed generalised cervical lymphadenopathy and hepatosplenomegaly. After intake of Ampicillin (prescribed by a local practitioner), the rash worsened. The most likely diagnosis is:

- (a) Dengue fever
- (b) Measles
- (c) Drug-rash
- (d) Infectious mononucleosis

90.

The phenomenon wherein normally innocuous stimuli produce pain is called:

- (a) Hyperalgesia
- (b) Allodynia
- (c) Analgesia
- (d) Sensitization

91.

A 76-year old male categorized as frail is likely to have overt changes in:

1. Body composition
2. Homeostatic dysregulation
3. Energetic failure
4. Neurodegeneration

Select the correct answer using the code given below:



Join Whatsapp

www.freejobalert.com
Free Job Alert
.com



Download App

- (a) 1, 2, 3 and 4
- (b) 1, 2 and 3 only
- (c) 2 and 4 only
- (d) 1 and 3 only

92.

Nitroglycerin is NOT used as an oral tablet because of its:

- (a) Poor solubility
- (b) Poor degradability
- (c) High pre systemic metabolism
- (d) Unpalatability

93.

Confabulation is a feature of the deficiency of:

- (a) Niacin
- (b) Folic acid
- (c) Thiamine
- (d) Zinc

94.

Following the bite of a snake, a patient develops generalised myalgias, rhabdomyolysis, and progressive flaccid paralysis. The most likely snake implicated is:

- (a) Cobra
- (b) Krait
- (c) Russel viper
- (d) Sea snake



Join Whatsapp

www.freejobalert.com
Free Job Alert
.com



Download App

95.

A 65-year old man, on Warfarin treatment, is started on antitubercular treatment. The pharmacologic effect of Warfarin is likely to:

- (a) Increase
- (b) Decrease
- (c) Remain the same
- (d) Be unpredictable and variable

96.

All of the following are components of the Wernicke's syndrome EXCEPT:

- (a) Ataxia
- (b) Ophthalmoplegia
- (c) Retrograde amnesia
- (d) Encephalopathy

97.

During Neonatal Resuscitation, chest compressions should be discontinued once the heart rate is:

- (a) ≥ 60 beats per minute
- (b) ≥ 80 beats per minute
- (c) ≥ 100 beats per minute
- (d) Regular on auscultation

98.

A 5 day-old neonate is brought with abdominal distention and non-passage of meconium since birth. On per rectal examination, the anal tone is normal and the rectum is empty of

faeces. There is rapid expulsion of faeces after the digital examination. Which test will help you to establish the diagnosis?



Join Whatsapp

www.freejobalert.com
Free Job Alert
.com



Download App

- (a) Rectal Manometry
- (b) Barium follow through contrast study
- (c) Rectal suction biopsy
- (d) Colonoscopy

99.

Which of the following advantages is NOT associated with delayed cord clamping in term babies?

- (a) Improvement in haematological status
- (b) Increased iron levels
- (c) Decreased levels of physiological anemia of infancy
- (d) Reduction in hyperbilirubinemia

100.

A term neonate delivered through meconium stained liquor, is found to be having poor respiratory efforts soon after birth. The most appropriate management for this child would be:

- (a) Intrapartum suctioning of mouth and nose before delivery of shoulders
- (b) Post natal tracheal suctioning
- (c) Immediate suctioning of mouth and nose
- (d) Initial steps of neonatal resuscitation

101.

Which one of the following figures should a five year old developmentally normal child be able to draw?

- (a) Rectangle
- (b) Triangle
- (c) Circle
- (d) Cross



Join Whatsapp

www.freejobalert.com
Free Job Alert
.com



Download App

102.

Which of the following manifestations is/are NOT seen in breath holding spells?

- (a) Apnea
- (b) Tonic clonic movements
- (c) Drowsiness after the episode
- (d) Pallor

103.

Which of the following toxidromes is associated with the consumption of pesticides

containing organophosphates?

- (a) Adrenergic
- (b) Serotonergic
- (c) Cholinergic
- (d) Hypnotic

104.

Which of the following is the primary antidote used in children with organophosphate

poisoning?

- (a) Atropine
- (b) Physostigmine
- (c) Sodium bicarbonate
- (d) Naloxone

105.

Till what age should corrected age be used (rather than chronological age) for the development assessment of babies born preterm?



Join Whatsapp

www.freejobalert.com
Free Job Alert
.com



Download App

- (a) 6 months
- (b) 1 years
- (c) 2 years
- (d) 2.5 years

106.

Which of the following is NOT a maternal risk factor for the development of a neural tube defect?

- (a) Insulin dependent Diabetes Mellitus
- (b) Exposure to radiation
- (c) Intake of Phenytoin
- (d) Folate deficiency

107. Trisomy 13 is also known as:

- (a) Edward syndrome
- (b) Patau syndrome
- (c) Turner syndrome
- (d) Williams syndrome

108.

Which one of the following is a type of glycogen storage disease?

- (a) Andersen disease
- (b) Gaucher disease
- (c) Krabbe disease
- (d) Sandhoff disease

109.

Which of the following biochemical tests for the detection of aneuploidies is performed in the first trimester of pregnancy?



Join Whatsapp

www.freejobalert.com
Free Job Alert
.com



Download App

- (a) Serum alpha-feto protein
- (b) Pregnancy associated plasma protein A
- (c) Unconjugated estriol
- (d) Inhibin A

110.

Which of the following is NOT a birth defect related to a disorder in the development of the whole eyeball?

- (a) Anophthalmos
- (b) Cryptophthalmos
- (c) Microphthalmos
- (d) Nanophthalmos

111.

Which of the following types of tracheoesophageal fistulae is the most common?

- (a) The upper part of the esophagus ends blindly and the lower end is connected to the trachea by a fistula
- (b) There is no fistulous connection between either the upper or the lower parts of the esophagus and the trachea
- (c) The upper part of the esophagus opens into the trachea
- (d) Both the upper and lower parts of the esophagus open into the trachea

112.

Which one of the following antiretroviral drugs is a Nucleoside reverse transcriptase inhibitor?

- (a) Amprenavir
- (b) Indinavir
- (c) Abacavir



Join Whatsapp

www.freejobalert.com
Free Job Alert
.com



Download App

(d) Nevirapine

113.

All of the following statements are true about the BCG vaccine EXCEPT:

- (a) It has 50–80% protection against military and meningeal forms of tuberculosis
- (b) It does not protect against other mycobacterial diseases like leprosy
- (c) It induces primary cell mediated immunity
- (d) There is interference with its effect due to maternal antibodies

114.

A 10 year-old boy has received complete pre exposure vaccination with the rabies vaccine. He is bitten on the hand by a stray dog within a year of the last dose. Which of the following will be the recommended treatment option?

- (a) Irrigation of the wound with water for ten minutes followed by povidone iodine (local care)
- (b) Local wound care and local infiltration with rabies Immunoglobulin (RIG)
- (c) Local wound care and 2 doses of rabies vaccine (day 0 and 3)
- (d) Local wound care and local infiltration of wound with RIG and 2 dose of rabies vaccine (day 0 and 3)

115.

Which of the following combinations of the Human Papilloma Virus (HPV) serotypes are non-oncogenic?

- (a) 6 and 11
- (b) 6 and 16
- (c) 6 and 18
- (d) 16 and 18

116.

What type of vaccine is the Rotavirus vaccine?



Join Whatsapp

www.freejobalert.com
Free Job Alert
.com



Download App

- (a) Live attenuated organism
- (b) Killed organism
- (c) Toxoid
- (d) Subunit vaccine

117.

What is the risk of recurrence for Down's syndrome when the underlying cause is a translocation inherited from the father?

- (a) 1%
- (b) 4–5 %
- (c) 10 %
- (d) 100%

118.

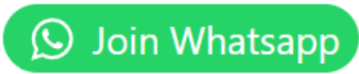
An 8 month old infant with evolving Cerebral Palsy is diagnosed with the first episode of Urinary Tract Infection. What further radiological evaluation should be planned?

- (a) Ultrasound of the abdomen (KUB) only
- (b) Ultrasound of the abdomen (KUB) and Micturating Cystourethrogram (MCU) only
- (c) Ultrasound of the abdomen (KUB), Micturating Cystourethrogram (MCU) and radionuclide renal scan (99Tc DMSCA scan)
- (d) Radionuclide or ultrasound scan (99Tc DMSA scan) followed by MCU (if required)

119.

Which one of the following vaccines is NOT included in Mission Indradhanush?

- (a) BCG
- (b) OPV
- (c) DPT



(d) MMR

120.

Which of the following drugs is NOT included in the management of Attention Deficit

Hyperactivity disorder?

(a) Amphetamine

(b) Atomoxetine

(c) Methylphenidate

(d) Trientine

FreeJobAlert.com